

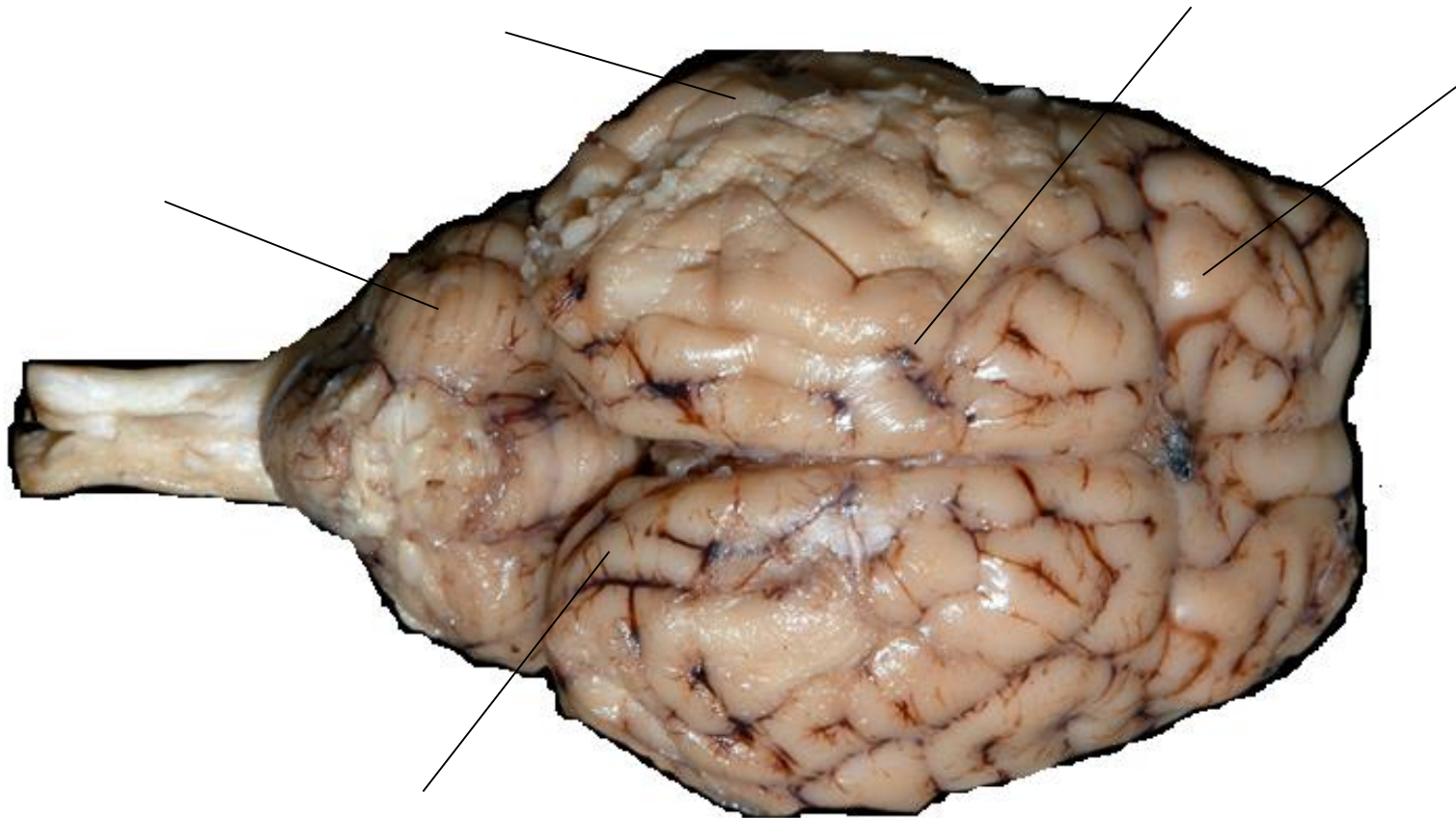
Name: \_\_\_\_\_  
Student ID: \_\_\_\_\_

Instructor: \_\_\_\_\_  
Section: \_\_\_\_\_

## **Sheep Neuroanatomy Lab- Labeling Worksheet**

Psychology 2315- Brain and Behaviour  
Kwantlen Polytechnic University

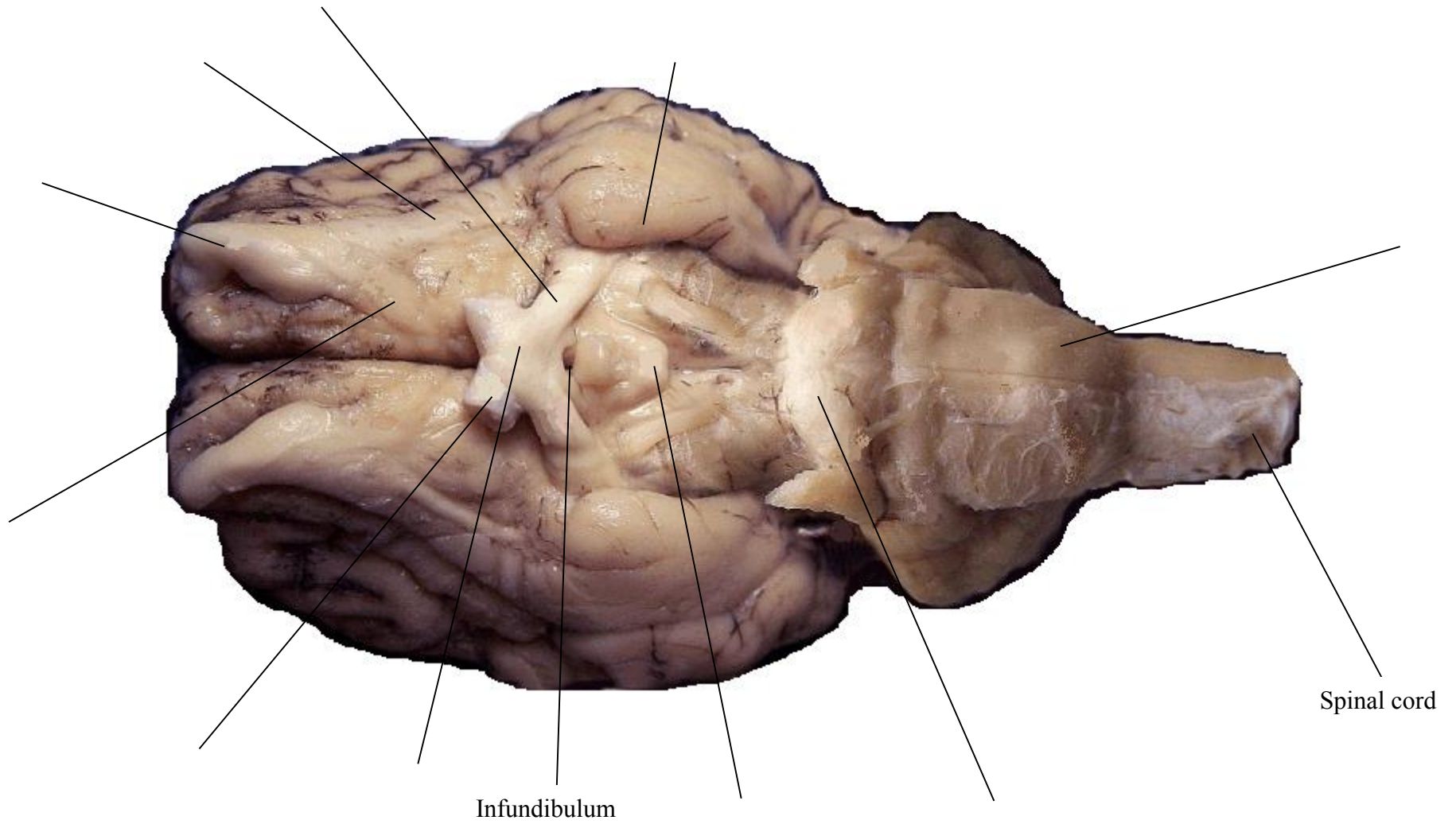
**Figure 1: Dorsal view**



**Cerebellum, Frontal lobe, Occipital lobe, Parietal lobe, and Temporal lobe.**

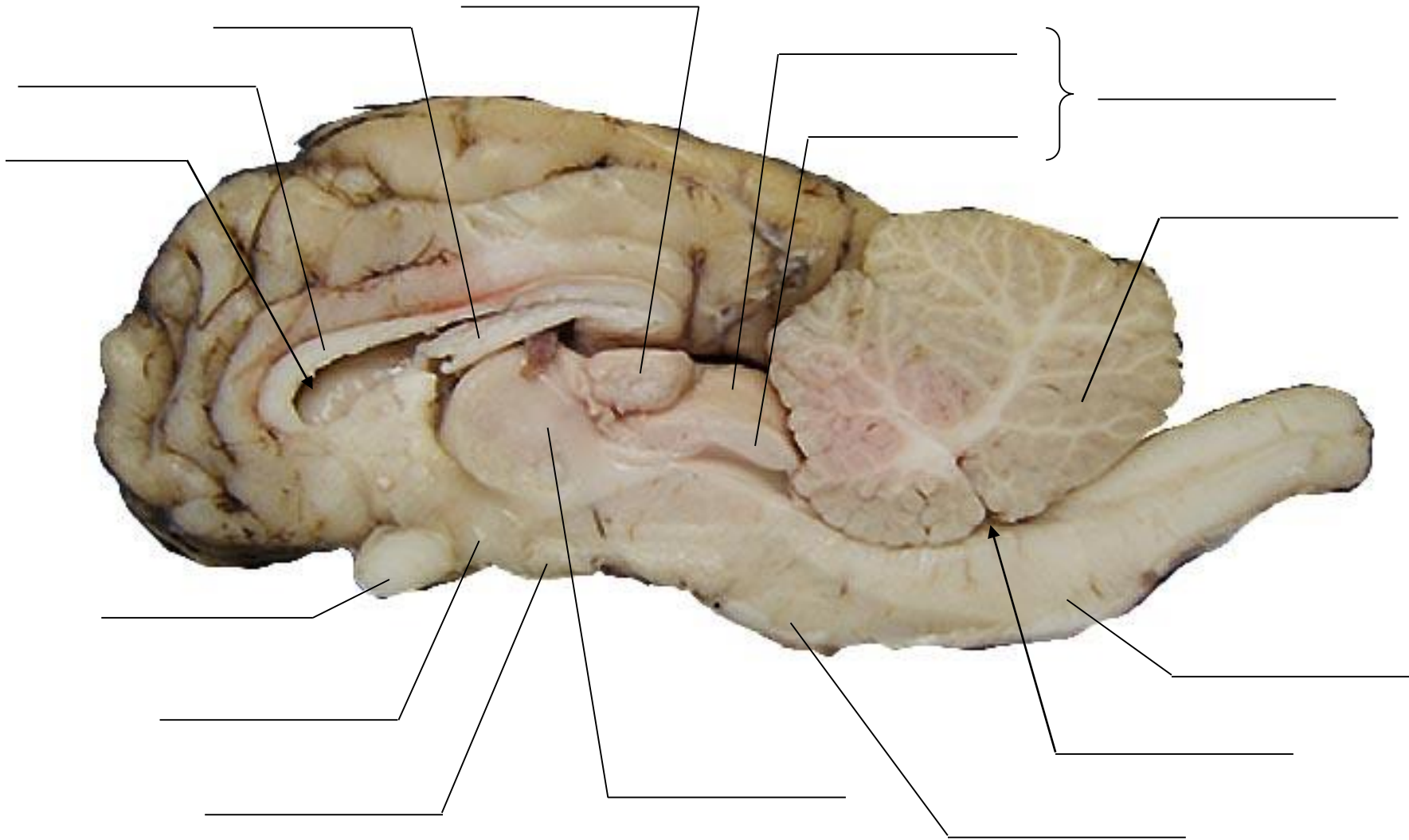
Periamygdaloid cortex, Optic tract, Medulla, Mammillary bodies, Lateral olfactory tract, Medial olfactory tract, Olfactory bulb, Optic nerve, Optic chiasm, Pons.

**Figure 2: Ventral view**



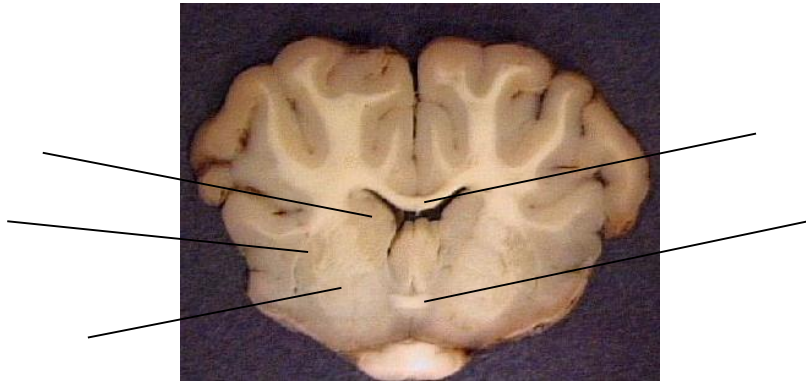
**Figure 3: Midsagittal section**

Fourth ventricle, Lateral ventricle, Fornix, Pineal gland, Superior colliculus, Corpus callosum, Inferior colliculus, Optic chiasm, Hypothalamus, Cerebellum, Medulla oblongata, Pons, Thalamus, Mammillary body, Tectum.



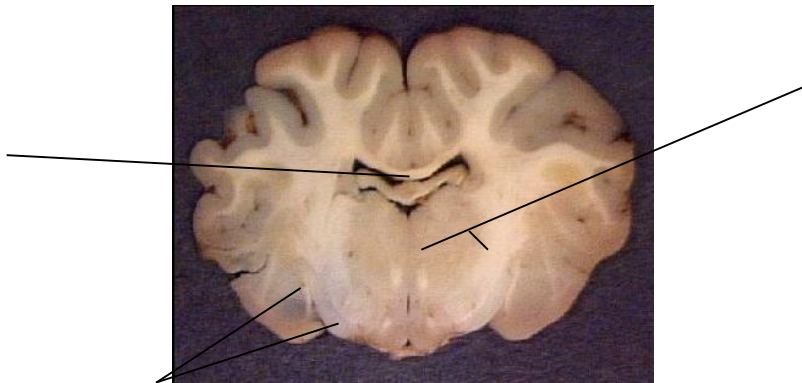
**Figure 4: Coronal section a**

Corpus callosum, Anterior commissure,  
Globus pallidus, Putamen, Caudate nucleus



**Figure 5: Coronal section b**

Amygdala, Thalamus, Fornix



**Figure 6: Coronal section c**

Pineal gland, Thalamus, Hippocampus

